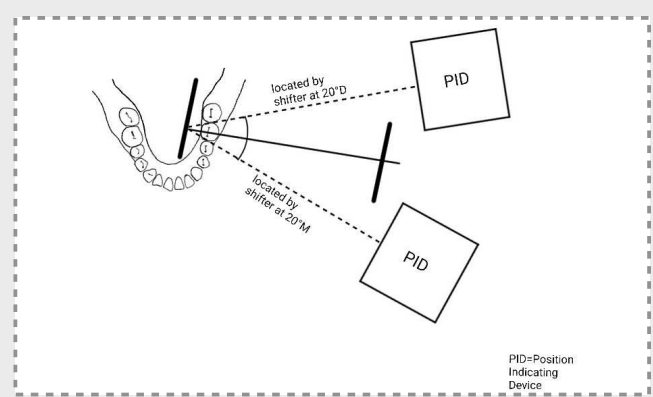


Introduction

Radiography is an important step in the root canal treatment. It is necessary to shift x-ray tube to separate the superimposed canals during the treatment. RSU Shifter, the innovation of Piyanuch and colleagues, can be used with EndoRay II (DentsplyRinn, PA, USA).

In this study, we focus on using RSU shifter 20° in both mesial and distal shift performing in the root canal treatment procedures. It is necessary to evaluate the accuracy and quality of RSU shifter in superimposed canals separation before widely using in the clinical practice.



Objective

To evaluate the efficacy and frequency of the RSU shifter 20 degrees in separating superimposed root canal in multi-rooted tooth both mesial and distal angulation of radiograph in endodontic procedures.



Methodology

The study involved three groups of 121 patients with two canals of 38 maxillary premolar, three canals of 44 and four canals of 39 mandibular molars that had been clinically determined for endodontic treatment. Two radiographs were taken from each tooth with varying horizontal angulations +20 (M), or -20 (D) degrees. Then the radiographic images of those angle x-ray beam were evaluated by two examiners.

Data analysis

- ▶ The strength of agreement between the radiograph evaluations of each examiner was evaluated using Kappa statistics.
- ▶ the significant differences between the percentages of radiographs were analyzed using the Chi-square test. The significance was set at $P < 0.05$

Diagnostic efficacy of 20° RSU shifter in superimposed canal separation

Results

- ▶ The strength of both intra and inter agreement values of both examiners indicated substantial-almost perfect agreement.
- ▶ The evaluations of the first and second examiners revealed that the percentage of distinctly separated root canals
 - Premolar : M shift 76.3% and 76.3%, D shift 68.4% and 71% ($P=0.489$ and 0.661)
 - Molar 3 canals : M shift 59% and 59%, D shift 68.1% and 70.4% ($P=0.002$ and 0.004)
 - Molar 4 canals : M shift 71.7% and 69.2%, D shift 51.2% and 53.8% ($P=0.003$ and 0.014)

Conclusion

Our results indicated that either a 20°M or 20°D shift resulted in the same distinctly separated root canals of maxillary premolar with two canals. In mandibular molar with three canals; -20°D shift gained a higher percentage of radiographs with distinctly separated root canals compared to +20°M shift. While +20°M shift demonstrated a higher percentage in mandibular molars with four canals.

The 20° RSU Shifter has the efficiency to separate superimposed root canals in the aspect of determining the precise shifted radiograph angle.



Advisor
Professor La-ongthong Vajrabhaya



Witchakorn San	Thanakittipoom Kuntiyaratana	5600161 5605715
Poonnika Sirikarn	Ratanachai Aneakgerawat	5605799 5605973
Boonkanda	Kaewduang	5605998