

An uncommon disorder with multiple skeletal anomalies: Gorlin-Goltz syndrome

Onur Keçeli¹, İlke Coskun-Benlidayı², M. Emre Benlidayı¹, Özgür Erdoğan¹

¹Department of Oral and Maxillofacial Surgery, Faculty of Dentistry, and ²Department of Physical Medicine and Rehabilitation, Cukurova University Faculty of Medicine, Adana, Turkey
E-mail: icbenlidayi@hotmail.com

SUMMARY: Keçeli O, Coşkun-Benlidayı İ, Benlidayı ME, Erdoğan Ö. An uncommon disorder with multiple skeletal anomalies: Gorlin-Goltz syndrome. Turk J Pediatr 2014; 56: 434-436.

Gorlin-Goltz syndrome is an uncommon disorder transmitted through autosomal dominant inheritance. This syndrome is characterized by multiple odontogenic keratocysts, along with congenital skeletal anomalies and basal cell carcinomas. A 16-year-old girl was admitted with a complaint of swelling on the lower jaw. She had multiple basal cell nevi on both hands. Multiple lytic bone lesions on radiographs were defined as odontogenic keratocysts following the biopsy. The patient was referred to the Department of Physical Medicine and Rehabilitation for detailed musculoskeletal evaluation. Adam's forward bend test revealed a hump on the right side representing right thoracic scoliosis. Cervical kyphosis, thoracic lordosis and scoliosis, bifid rib and sacral and lumbar spina bifida on plain radiographs led to the diagnosis of Gorlin-Goltz syndrome. Since early diagnosis may provide optimum surveillance for related neoplasms, it is of paramount importance for pediatricians as well as physicians dealing with the musculoskeletal system to be aware of this rare condition.

Key words: Gorlin-Goltz syndrome, odontogenic keratocysts, scoliosis, skeletal anomalies, vermis dysgenesis.

Gorlin-Goltz syndrome is an uncommon disorder transmitted through autosomal dominant inheritance¹⁻³. This syndrome, also known as basal cell nevus syndrome or nevoid basal cell carcinoma syndrome, has an estimated prevalence varying from 1/57,000 to 1/256,000^{4, 5}. Germline mutations in a tumor suppressor gene named the patched (PTCH1) gene located at chromosome 9q22.3 are responsible for this rare syndrome^{6, 7}. Gorlin-Goltz syndrome is characterized by basal cell carcinomas along with multiple odontogenic keratocysts and congenital skeletal anomalies. However, it can present with a wide variety of manifestations with regard to the urogenital and central nervous system.

The modified set of diagnostic criteria by Kimonis et al.⁸ are as follows:

a) Major criteria: More than two basal cell carcinomas or one before age 20; histopathologically proven odontogenic keratocysts of the jaws 3 or more palmar or plantar pits; bilamellar calcification of the falx cerebri; bifid, fused or markedly splayed

ribs; a first-degree relative with Gorlin-Goltz syndrome,

b) Minor criteria: Macrocephaly determined after adjustment for height; congenital malformation (cleft lip or palate, frontal bossing, coarse face, moderate or severe hypertelorism); other skeletal abnormalities (Sprengel deformity, marked pectus deformity, marked syndactyly of the digits); radiological abnormalities (bridging of the sella turcica, vertebral anomalies such as hemivertebrae, fusion or elongation of the vertebral bodies, modeling defects of the hands and feet, or flame shaped lucencies of the hands or feet); ovarian fibroma; medulloblastoma.

Two of the major signs or one major and two minor signs are required for the diagnosis of Gorlin-Goltz syndrome⁸.

Case Report

A 16-year-old girl was admitted with a complaint of swelling on the lower jaw to the Department of Oral and Maxillofacial Surgery. General examination revealed swelling of the lower jaw, multiple basal cell nevi on

both hands and pits on the palms. Intraoral examination revealed dental crowding and bilateral swelling on the mandible. Panoramic radiography showed multiple radiolucent bone lesions in the mandible and maxilla, while cerebral magnetic resonance imaging revealed vermian dysgenesis (Fig. 1). Following the pathological diagnosis of odontogenic keratocyst by incisional biopsy, the patient was referred to the Department of Physical Medicine and Rehabilitation for detailed musculoskeletal examination. On physical examination, the patient was 156 cm in height and 52 kg in weight. The head circumference was 57.5 cm, which is compatible with macrocephaly. Adam's forward bend test revealed a hump on the right side representing right thoracic scoliosis. Cervical kyphosis, thoracic lordosis and scoliosis, bifid left third rib and sacral and lumbar spina bifida determined on plain radiographs led to the diagnosis of Gorlin-Goltz syndrome (Fig. 2). The odontogenic cysts were enucleated under general anesthesia. Routine

follow-up was planned in order to evaluate the plausible recurrence of cysts and the progression of scoliosis.

Discussion

Gorlin-Goltz syndrome is an uncommon disorder with various manifestations. There are several reported cases of Gorlin-Goltz syndrome in the literature¹⁻³.

The odontogenic keratocysts that accompany this uncommon syndrome exhibit biological aggression and high risk of recurrence due to the high mitotic epithelial activity and frequency of satellite cysts^{9, 10}. Treatment of the keratocysts varies from enucleation with peripheral osteotomies to resections^{11, 12}. If the treatment of odontogenic keratocysts is neglected, the cysts may develop into severe complications such as jaw fractures or migration or mobilization of the teeth. Therefore, patients should be informed about the significance of odontogenic keratocysts and the likelihood of the development of further cysts.

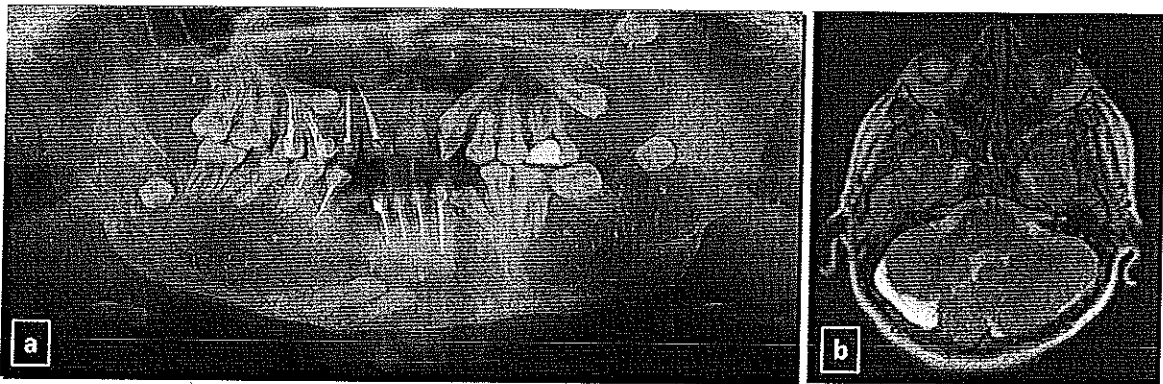

Fig. 1. (a) Multiple odontogenic keratocysts on a panoramic radiograph. (b) Vermian dysgenesis.

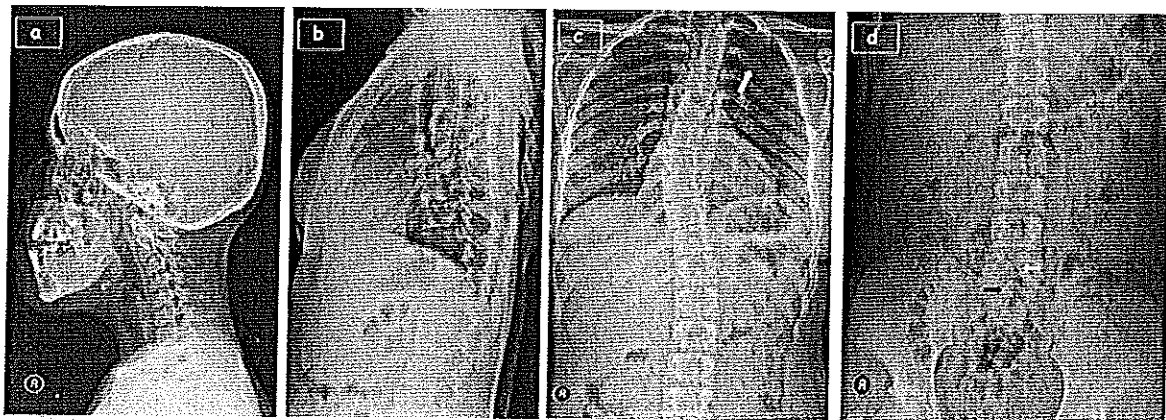


Fig. 2. Skeletal anomalies of Gorlin-Goltz syndrome. (a) Cervical kyphosis; (b) Thoracic lordosis; (c) Scoliosis; (d) Bifid rib (white arrow); (e) Lumbar spina bifida (white arrow), sacral spina bifida (black arrow).

From a skeletal point of view, Gorlin-Goltz syndrome may present with multiple musculoskeletal manifestations in the early years of life. Skeletal anomalies include bifid, splayed, fused, or misshapen ribs, widened ends of the clavicles, fusion of vertebrae, hemivertebrae, scoliosis, flame-shaped lucencies of the metacarpals and/or phalanges, spina bifida occulta and short 4th metacarpals. Calcification of the falx cerebri, tentorium cerebelli and nuchal ligament are also common radiological findings of this rare syndrome¹³. Scoliosis is one of the most relevant skeletal manifestations. Its diagnosis is based primarily on physical examination. In addition, plain radiography of the thoracolumbar spine is needed for further evaluation, management and follow-up. The main goal of scoliosis management is to impede curvature progression. Protecting pulmonary function and combating pain are the other aims of treatment. Conservative scoliosis management includes physical therapy, an intensive scoliosis rehabilitation program and braces¹⁴. Surgical approaches may be considered for selected cases.

Gorlin-Goltz syndrome can present with multiple, recurrent odontogenic keratocysts, basal cell carcinomas and skeletal anomalies. However, patients may not necessarily present with all of the major features such as basal cell carcinomas, jaw cysts or falx calcification, which are often not evident until the teen years. Furthermore, although genetic analysis is an important determinant of diagnosis, only about 60-85% of individuals tested by sequencing of PTCH1 have mutations. For the remaining cases, other manifestations that can be detected by physical examination and radiographic evaluation have a crucial role in the early diagnosis of this syndrome, which provides optimum surveillance for related neoplasms¹³. Skeletal anomalies displaying a wide range of variety may be determined incidentally in a case without a prior diagnosis of Gorlin-Goltz syndrome. For instance, chest radiographs ordered by pediatricians for other reasons may show the rib anomalies. Spina bifida, scoliosis, hemivertebrae and fused vertebrae can be detected on thoracolumbar plain radiographs of patients being admitted to pain units owing to back pain. Scoliosis, which can be easily recognized by both physical and radiological examination, may be the first

feature of this syndrome to be determined in a patient with mechanical back pain. In this way, musculoskeletal anomalies may bring to light the possibility of Gorlin-Goltz syndrome, thereby assisting in earlier diagnosis.

REFERENCES

1. Gorlin RJ. Nevoid basal-cell carcinoma syndrome. *Medicine (Baltimore)* 1987; 66: 98-113.
2. Tümer C, Er N, Balci S, Ataç A. Two male patients with nevoid basal cell carcinoma syndrome from Turkey. *Turk J Pediatr* 2001; 43: 351-355.
3. Ozturk A, Oguz KK, Tumer C, Balci S. Neuroradiological findings in a mother and daughter with Gorlin syndrome. *Clin Dysmorphol* 2003; 12: 145-146.
4. Kiwilsza M, Sporniak-Tutak K. Gorlin-Goltz syndrome - a medical condition requiring a multidisciplinary approach. *Med Sci Monit* 2012; 18: RA145-153.
5. Pandeshwar P, Jayanthi K, Mahesh D. Gorlin-Goltz syndrome. *Case Rep Dent* 2012; 2012: 247239.
6. Soufir N, Gerard B, Portela M, et al. PTCH mutations and deletions in patients with typical nevoid basal cell carcinoma syndrome and in patients with a suspected genetic predisposition to basal cell carcinoma: a French study. *Br J Cancer* 2006; 95: 548-553.
7. Lü Y, Zhu HG, Ye WM, Zhang MB, He D, Chen WT. A new mutation of PTCH gene in a Chinese family with nevoid basal cell carcinoma syndrome. *Chin Med J (Engl)* 2008; 121: 118-121.
8. Kimonis VE, Goldstein AM, Pastakia B, et al. Clinical manifestations in 105 persons with nevoid basal cell carcinoma syndrome. *Am J Med Genet* 1997; 69: 299-308.
9. Ortega García de Amezaga A, García Atregui O, Zepeda Nuño S, Acha Sagredo A, Aguirre Urizar JM. Gorlin-Goltz syndrome: clinicopathologic aspects. *Med Oral Patol Oral Cir Bucal* 2008; 13: E338-343.
10. Lo Muzio L, Staibano S, Pannone G, et al. Expression of cell cycle and apoptosis-related proteins in sporadic odontogenic keratocysts and odontogenic keratocysts associated with the nevoid basal cell carcinoma syndrome. *J Dent Res* 1999; 78: 1345-1353.
11. Manfredi M, Vescovi P, Bonanini M, Porter S. Nevoid basal cell carcinoma syndrome: a review of the literature. *Int J Oral Maxillofac Surg* 2004; 33: 117-124.
12. Gu XM, Zhao HS, Sun LS, Li TJ. PTCH Mutations in sporadic and Gorlin-syndrome-related odontogenic keratocysts. *J Dent Res* 2006; 85: 859-863.
13. Kimonis VE, Mehta SG, Digiovanna JJ, Bale SJ, Pastakia B. Radiological features in 82 patients with nevoid basal cell carcinoma (NBCC or Gorlin) syndrome. *Genet Med* 2004; 6: 495-502.
14. Weiss HR, Negrini S, Rigo M, et al. Indications for conservative management of scoliosis (guidelines). *Scoliosis* 2006; 1: 5.

()

()

... ..