



## The effect of Phayayor oral paste on gingival healing of extraction wound: a pilot study

Wachiraporn Peethong<sup>1</sup>, Laddawun Sununliganon<sup>1</sup>, Mallika Tong-in<sup>1</sup>, Nongnapas Chareoncharsri<sup>1</sup>, Prapatsorn Porkpermdee<sup>1</sup>, Wachayanun Sriprasert<sup>1</sup> and Nuttawut Supachawaroj<sup>\*,1</sup>.

<sup>1</sup>Department of Oral Surgery, College of Dental medicine, Rangsit University, Pathum Thani, Thailand

\*Corresponding author, E-mail: nuttawut.s@rsu.ac.th

### Abstract

Phayayor oral paste is one of the Thai traditional herbs. It has a low price that can be easily accessed. It has been confirmed that Phayayor extract is safe for living organisms and it has an effect on wound healing

The effect of Phayayor oral paste on the gingival healing of extraction wounds was investigated in this study.

This study collects data from patients who visit the Oral surgery department of the College of Dental Medicine, Rangsit University for simple tooth extraction from February 2021 to January 2022. The data were collected among the patients aged 18 to 60 years old, and 22 subjects. The study and control groups were chosen by using two block randomizations. The experiment is to suture the simple extraction wound with one to two stitches with silk 4/0. Then apply a Phayayor oral paste to the tooth extraction wound in the study group and measure the distance of wound healing. On days 0, 3, and 5, the examiner used a dental caliper and digital caliper to measure the distance of wound healing.

On days 3 and 5, the percentage changes of wound distance in the control group were  $13.46 \pm 8.84$  and  $39.78 \pm 13.83$ , respectively, while the percentage changes of wound distance in the study group were  $36.28 \pm 16.94$  and  $65.57 \pm 7.28$ . On days 3 and 5, the percentage of wound distance in the study group was substantially higher than in the control group. The assessment of the distance of wound healing of the control group on days 0-3 is  $0.58 \pm 0.42$  and on day 3-5 is  $1.24 \pm 1.08$  which means the difference is  $-0.65 \pm 1.38$ . The result revealed that the assessment of the distance of wound healing of the study group on days 0-3 is  $1.80 \pm 0.82$  and on day 3-5 is  $1.42 \pm 0.60$  which means the difference is  $0.37 \pm 1.34$ . The distance between wound healing of the control group and the study group on days 0-3 and days 3-5 is not statistically different at  $p < 0.05$ .

Phayayor can accelerate wound healing in the first 5 days after the simple extraction.

**Keywords:** *Clinacanthus nutans* (Burm.F.) Lindau, Phayayor, simple extraction wound, dental caliper, digital caliper

### 1. Introduction

Tooth extraction is a common procedure in dental treatment. The physiology of normal wound healing consists of four phases including hemorrhage, inflammatory, proliferative, and remodeling phases (George Broughton, Janis, & Attinger, 2006). Normally, epithelialization begins approximately 24 hours after the extraction. Guo and DiPietro (2010) reported that each individual has his healing capability determined by the biotype and biological profile, consisting of cytokines and inflammatory mediators. These factors may be altered by aging, obesity, smoking, or medical treatment received such as radiotherapy. Especially patients with systemic conditions, for instance, diabetes mellitus, connective tissue disorders, nutritional deficiency, and immunocompromised patients, are prone to delayed wound healing.

Nowadays, herbal medicine has been increasing as an alternative way because it is affordable and has fewer side effects in comparison with synthetic compounds. There are many herbs used in dentistry. For example, *Aloe barbadensis* Miller (Aloe vera), and *Elephantopus scaber* L. (Prickly-leaved elephant's foot). One of the herbs that are popular in Southeast Asia is *Clinacanthus nutans* (Burm.F.) Lindau (Phayayor) is used for treating oral ulcers or mucositis. (Putwatana et al. 2019)

Em-on Chaiprateepa and Thavornwatb (2018) reported Phayayor (*Clinacanthus nutans* (Burm.F.) Lindau), known as snake grass belonging to the Acanthaceae family, has been used for over the years in Malaysia, Indonesia, Thailand, and China. Ariful Alam et al. (2016) reported Phayayor contains various

[XXX]



bioactive compounds such as glycolipids, pheophytins, sterols, cerebrosides, sulfur-containing glycosides, and triterpenoids such as lupeol. The most important compounds are flavonoids and purpurin-18 phytol ester which perform an important role in wound healing in terms of anti-inflammation, promoting cell migration and cell proliferation. This plant is used in traditional herbal medicine as an anti-snake venom, for treating skin rashes, insects and scorpion bites, lesions caused by herpes simplex virus, diabetes, and gout. Recently, different preparations of Phayayor have been included in the Thai National List of Essential Medicines (2020) such as cream for herpes and varicella-zoster treatment, solution (intraoral) for aphthous ulcers treatment and chemo/radiotherapy, lotion for treating skin rash and urticaria and paste for treating inflammation and insect bites. It is also increasingly seen in many products such as toothpaste and mouthwash.

Aslam et al. (2016) found that flavonoids increase the antioxidant activity that surges the rate of wound contraction while purpurin-18 phytol ester exhibits anti-inflammation, in-vitro wound healing, and anti-biofilm activity. Tanasomwong (1986) found that the flavonoid compound showed anti-inflammatory action involved in the inhibition of prostaglandin synthesis. There is an experimental research study about the effect of Phayayor on gingival healing which is the study by Choonate, Korsuwannawong, and Chairatvit (2014). It is the study about the proliferative effect of Phayayor glycerine and *Moringa oleifera* seed oil extraction on cell proliferation. The study revealed that Phayayor glycerine promotes cell proliferation on human gingival fibroblast cell lines. Another study is the study by Srichan, Korsuwannawong, and Mala (2015), which studied the effect of Phayayor on cell proliferation and cell migration in the human gingival fibroblast cell line. The study revealed that Phayayor extracts promote cell proliferation and cell migration. Also, Phayayor extracts will affect the most on the first 5 days of gingival healing which is suggested as an alternate adjunctive regimen for oral wound healing. Most of the research about Phayayor is experimental research. Few clinical types of research show low evidential strength of research design. The clinical research by Putwatana et al. (2009) revealed that Glycerin Phayayor was effective, safe, and well-tolerated for prophylaxis and alleviation of radiation-induced oral mucositis. Until now, there is no clinical research study about the effect of Phayayor on tooth extraction wound healing.

This study aims to evaluate the effect of Phayayor on gingival healing of simple tooth extraction wounds.

## 2. Objectives

To evaluate the effect of Phayayor on gingival healing of simple tooth extraction wounds and to compare the effect of Phayayor on gingival healing of simple tooth extraction wounds on day 0, day 3, and day 5.

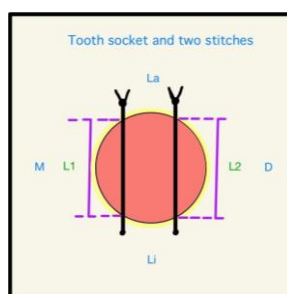
## 3. Materials and Methods

This is a pilot study of randomized controlled clinical trials. The sample size was justified according to Kieser and Wassmer (1998). Twenty-two participants who required simple dental extraction in the Department of Oral Surgery, The College of Dental Medicine, Rangsit University were recruited for the study. In this study, the simple dental extraction was referred to as tooth extraction with only dental elevator and forceps technique without flap opening and the operation time was less than 30 minutes. The inclusion criteria were volunteers whose ages were between 18 and 60 years, no systemic diseases that could affect wound healing, no periodontitis, no pregnancy, no allergy to Phayayor oral paste drugs, and local anesthesia. In addition, they were obligated to comply with the follow-up periods on days 3 and 5 after tooth extraction. Exclusion criteria were those who had taken related drugs (antibiotic, non-steroid anti-inflammatory drugs, or steroids) within two weeks. Intraoperative exclusion criteria were fracture alveolar bone, abnormal bleeding, or dental extraction other than a simple dental extraction method. Postoperative exclusion criteria were infection, early dislodged of the stitches (reference lines), or taking additional drugs that could affect wound healing. Participants were informed about the research details and those who fulfilled the above-mentioned criteria and provided written consent proceeded with the research. They were randomly assigned into either control or study group using the two blocks randomization technique. One to two stitches of 4/0 black silk (Thysilk®) were applied to each wound as the reference lines for the wound measurement. The

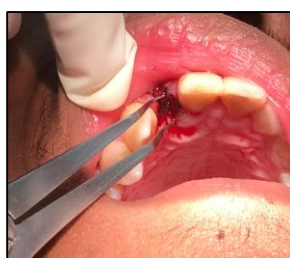[XXX]



mesial stitch was defined as L1 and the distal stitch was defined as L2 (Figure 1). Participants were advised to bite gauze for 15 minutes for hemostasis. The wound distance was measured by a blinded evaluator using a dental caliper placed at the wound margin and the stitches are used as the reference lines from the buccal to lingual/palatal sides (Figure 2). Then the distance was transferred to a digital caliper to measure the result in 2-digit numbers.



**Figure 1** Diagram of the tooth socket and two stitches



**Figure 2** The wound distance was measured by using a dental caliper placed at the wound margin

The Phayayor oral pastes were given to the study group with the home-use instruction as followed. The wound and the adjacent area must be cleaned before applying the oral paste. Phayayor oral paste (Herb & Hope®) on the wound 4 times a day with provided checklist-time using a cotton swab or the finger. The participants were not allowed to drink or have any food within thirty minutes after the oral paste application. However, the Phayayor oral pastes or any other placebo were not given to the control group as it represents normal gingival wound healing.

Aside from that part, both the control and study groups were given the same post-operative instruction for the simple extraction wound. The participants from both groups were instructed to bite down the gauzes for one hour or until the bleeding stopped. It also included brushing gently at the extraction wound, avoiding rinsing hard, no picking or sucking the wound area, no smoking and alcohol consumption, and only a soft diet was allowed in the first 2-3 days. Acetaminophen 500 mg was given as needed for pain relief every 6 hours. Participants who experienced any severe pain or discomfort including prolonged bleeding and facial swelling were required to return to the dentists.

On days 3 and 5 post-operation, healing of the wounds was monitored and wound distances were measured by a single researcher with a blind study.

#### 4.1 Results

This study was a pilot study. Twenty-two subjects were evaluated in this study which was separated into study group and control group equally by using two-block randomization. Data analysis was performed using the Statistical Package for Social Sciences (SPSS for Windows, version 20.0; SPSS Inc., Chicago, IL, USA). The data were normally distributed by the Shapiro-Wilks analysis. Afterward, comparing the clinical wound healing of tooth extraction wounds between the control group and the study group which was applying Phayayor oral paste for 5 days. The 2 subjects (1 in the study group and 1 in the control group) were excluded

[XXX]



from the study due to loss of follow-up and unable to control bleeding after tooth extraction. Finally, the study was carried out on 20 subjects. The participants consisted of 3 men and 7 women in the control group, with a mean±SD age of 47.13±12.23 years, and 2 men and 8 women in the study group, with a mean±SD age of 39.56±19.46 years. According to the study by Srichan et al., 2015, Phayayor can stimulate wound healing significantly over 5 days. Therefore, in this study, we measure the size of wound length on the day of extraction, day 3 as it exhibits rapid growth of proliferation, and day 5 which is the peak of the proliferation phase.

**Table 1** Comparison of the demographic characteristics of patients in study and control groups

Variable	Study group	Control group
	(N=10) Mean±SD	(N=10) Mean±SD
Age	39.56±19.46	47.13±12.23
	N	N
Sex	Male	3
	Female	7

To evaluate which phase of wound healing that Phayayor has affected gingival healing on a simple extraction wound, we calculate the percentage changes of wound distance by using the Unpaired t-test.

$$\% \text{Changes in wound distance} = \frac{\text{initial wound distance} - \text{specific day wound distance}}{\text{initial wound distance}} \times 100$$

According to Table 2, the result revealed that the assessment of the percentage changes of wound distance in the control group on day 3 is 13.46±8.84 while the assessment in the study group is 36.28±16.94, and the percentage changes of wound distance on day 5 in the control group are 39.78±13.83 while the percentage changes of wound distance in the study group are 65.57±7.28.

The result revealed that the percentage changes of wound distance in the study group are significantly different from the higher percentage changes of wound distance compared to those in the control group (*p-value* at 0.05). Thus, the gingival healing in the study group is more than in the control group.

**Table 2** The comparison of the mean and standard deviations of the percentage changes of wound distance in the control group and the study group on day 3 and day 5

The percentage changes in wound distance	Control	Study	P
Day 3	13.46±8.84	36.28±16.94	0.001*
Day 5	39.78±13.83	65.57±7.28	0.000*

\*Statistical significant (*p*<0.05)

To evaluate the distance of wound healing (mm.) by using the Paired t-test,

$$\text{Day 0-3} = \text{Distance of wound Day 0} - \text{Distance of wound Day 3}$$

$$\text{Day 3-5} = \text{Distance of wound Day 3} - \text{Distance of wound Day 5}$$

[XXX]



**Table 3** The comparison of the mean and standard deviations of the distance of wound healing (mm.) in the control group and study group on day 0-3 and day 3-5

	Distance of wound healing	Mean	Std. Deviation	Mean difference	Std. Deviation difference	t	P
Control group	Day 0-3	0.58	0.42				
	Day 3-5	1.24	1.08	-0.65	1.38	-1.50	0.17
Study group	Day 0-3	1.80	0.82				
	Day 3-5	1.42	0.60	0.37	1.34	0.87	0.40

This table shows the difference in wound healing of the control group and the study group between days 0-3 and 3-5. The assessment of the distance of wound healing of the control group on days 0-3 is  $0.58 \pm 0.42$  and on days 3-5 is  $1.24 \pm 1.08$  which means the difference is  $-0.65 \pm 1.38$ . The result revealed that the assessment of the distance of wound healing of the study group on days 0-3 is  $1.80 \pm 0.82$  and on days 3-5 is  $1.42 \pm 0.60$  which means the difference is  $0.37 \pm 1.34$ . The distance of wound healing between the control group and the study group on days 0-3 and days 3-5 is not statistically different at  $p < 0.05$ .

#### 4.2 Discussion

Our study, the effect of Phayayor (*Clinacanthus nutans* (Burm.F.) Lindau) on gingival healing of extraction wounds, has found that Phayayor oral paste promotes extraction wound healing in the first 5 days after the extraction. There is a statistically significant difference in the percentage changes of wound distance between the study group and control group ( $p < 0.05$ ) which in the study group is more than the control group. This is related to the experimental study by Srichan et al. (2015), the study evaluation of the proliferative and cell migration effect of Phayayor powder on human gingival fibroblast. It was found that *C. nutans* extracts had increased the proliferation of gingival fibroblast cells in the first 5 days before decreasing its rate.

Aslam et al. (2016) found that in Phayayor there were flavonoids, which enhanced the rate of wound healing, and purpurin-18 phytol ester, which exhibited anti-inflammation and in-vitro wound healing. The study of Tanasomwong (1986) found that it was because the flavonoid inhibits prostaglandin synthesis which is an essential substance in an inflammatory action. Although the effect of *Phayayor* on promoting re-epithelialization of soft tissue was primarily focused on in the study, the extracts of *C. nutans* have been used for the treatment of insect bites, allergic responses, herpes simplex, including gout and rheumatism due to its anti-inflammatory property (Sangkitporn et al., 1993). In the study by Em-on et. al in 2018, a triterpenoid called *Lupeol* found in *C. nutans* is strongly associated with the anti-inflammatory and antinociceptive activity by decreasing the inflammation response to indomethacin (selective cyclooxygenase inhibitor), in arthritis, and disease about inflammatory animal models. Another study by Teshima et. al (1997) about the anti-inflammatory activity in medical uses found that 80% ethanol extract of the aerial part of Phayayor showed significant inhibition of the generation of superoxide anion and the elastase release by activated neutrophils. Therefore, further research about the anti-inflammatory action of *C. nutans* extracts on wound healing e.g., healing index, and pain score should be studied and developed in future times.

The method to measure soft tissue wound healing can be established more accurately with nowadays technologies. Intraoral scanner devices are becoming widespread in clinical dental practice due to many of their advantages over conventional methods. In the study by Mangano et. al (2017), the intraoral scanner uses the overlapping of images and reverse-engineering software to generate colorimetric maps displaying the distances and differences between surfaces at the microscopic level. It is an efficient way to follow up on the treatment progress, especially in a short-span area. Hence, by applying IOS in tracking soft tissue healing and evaluating the percentage change of wound area in future research, the result could be more precise and less biased than the manual technique used in the study.

In general, several concepts have been developed to assess soft tissue wound healing. For instance, the Healing index (HI) was invented by Landry, Turnbull, and Howley in 1998. They used the parameter of

[XXX]



tissue colours, response to palpation, granulation tissue, incision margins, and the presence of suppuration. The next index is the Early Healing Index (EHI) by Wachtel et al. which classifies soft tissue healing in 5 aspects relating to the rate of flap closure, amount of fibrin, and necrosis tissue. Moreover, Hagenars et al. (2004) used a 3-point score to evaluate the colour and swelling of the gingival tissues. Also, Li, Huang, and Hsu. (2005) developed the Wound Healing Index (WHI) in order to assess periodontal soft tissue and wound healing by the scores from 1 to 3. The scores were used to assess gingival oedema, erythema, suppuration, patient discomfort, and flap dehiscence. Although these methods have been used as references for assessing soft tissue healing after the injuries, most of their indexes are not appropriate to be used in the early stages of the healing. The reason might be explained by the complexity of biological and clinical wound healing procedures. Considering these limitations, this pilot study was developed in order to more accurately assess the early stage of tissue wound healing due to the fact that the epithelialization process starts within the first 24 to 48 hours after the injury. For that reason, the concept of using the re-epithelialization phase as another indicator in the wound healing of soft tissue would fill the missing gap in future studies to come.

The outcome of this pilot clinical study that Phayayor has no toxicity to cells could be supported by the results from the in vitro studies by Choonate et al. (2014), and Srichan et al. (2015). Therefore, Phayayor might be able to be used as a potential medicine for the wound healing process in dentistry.

## 5. Conclusion

Phayayor extracts accelerate the wound healing in the first 5 days after the extraction but since this study is a pilot study, more participants should be added to make the result more confident that it can be further developed and applied in dentistry.

## 6. Acknowledgements

This research was supported by The Research Institute and College of Dental Medicine, Rangsit University, Thailand. We sincerely appreciated the support. Herb and Hope CO., LTD for sponsor Phayayor oral paste.

## 7. References

- Aslam, M. S., Ahmad, M. S., Mamat, A. S., Ahmad, M. Z., & Salam, F. (2016). Antioxidant and wound healing activity of polyherbal fractions of *Clinacanthus nutans* and *Elephantopus scaber*. *Evidence-based Complementary and Alternative Medicine*, 2016.
- Chaiprateep, E., Thavornwat, C. (2018). Optimization of *Clinacanthus nutans* biogradable analgesic patch. *Natural product communications*, 13(12). 1569-1572.
- Choonate, S., Korsuwannawong, S., Chairatvit, K. (2014). Evaluation of the proliferative effect of *Clinacanthus nutans* glycerine and moringa oleifera seed oil extraction on human gingival fibroblast cell line. *Mahidol Dental Journal*, 34(3), 373-384.
- George Broughton, I. I., Janis, J. E., & Attinger, C. E. (2006). Wound healing: an overview. *Plastic and reconstructive surgery*, 117(7S), 1e-S.
- Hagenars, S., Louwse P. H. G., Timmerman M. F., Velden U. V., and Weijden G. A. V. (2004). Soft-tissue wound healing following periodontal surgery and Emdogain application. *J Clin Periodontol*, 31(10), 850-6. Doi: <https://doi.org/10.1111/j.1600-051x.2004.00571.x>
- Landry, R. G., Turnbull, R. S., Howley, T. (1988). Effectiveness of benzydamyne HCl in the treatment of Periodontal post-surgical patients. *Res Clin Forum* 1988; 10:105
- Li, S., Huang, N. F., & Hsu, S. (2005). Mechanotransduction in endothelial cell migration. *Journal of cellular biochemistry*, 96(6), 1110-1126. Doi: <https://doi.org/10.1002/jcb.20614>
- Mangano, F., Gandolfi, A., Luongo, G., & Logozzo, S. (2017). Intraoral scanners in dentistry: a review of the current literature. *BMC oral health*, 17(1), 1-11. Doi: <https://dx.doi.org/10.1186%2Fs12903-017-0442-x>
- Putwatana, P., Sanmanowong, P., Oonprasertpong, L., Junda, T., Pitiporn, S., & Narkwong, L. (2009). Relief of radiation-induced oral mucositis in head and neck cancer. *Cancer Nursing*, 32(1), 82-87.

[XXX]



- Sangkitporn, S., Polchan, K., Balachandra, K., Dechatiwongse na Ayudhaya, T., Bunchob, M., and Jayavas, C. (1993). Treatment of Herpes Zoster Patients with *Clinacanthus nutans* Extract. *Journal of the Medical Association of Thailand*, 78 (11), 624-627.
- Srichan, R., Korsuwannawong, S., Mala, S. (2015). Evaluation of the proliferative and cell migration effect of *Clinacanthus nutans* powder on the human gingival fibroblast cell line. Research office, Faculty of Dentistry, Mahidol University. *M Dent J*, 35(3), 299-310.
- Tanasomwong, W. (1986). *The screening of anti-inflammatory action of Clinacanthus nutans (Burm.f.) Lindau: a critical evaluation of carrageenan-induced hindpaw edema model*. Doctoral dissertation, Mahidol University.
- Teshima, K. I., Kaneko, T., Ohtani, K., Kasai, R., Lhieochaiphant, S., Picheansoonthon, C., & Yamasaki, K. (1998). Sulfur-containing glucosides from *Clinacanthus nutans*. *Phytochemistry*, 48(5), 831-835.
- Velnar, T., Bailey, T., & Smrkolj, V. (2009). The wound healing process: an overview of the cellular and molecular mechanisms. *Journal of International Medical Research*, 37(5), 1528-1542.
- Wanikiat, P., Panthong, A., Sujayanon, P., Yoosook, C., Rossi, A.G., and Reutrakul, V. (2008). The anti-inflammatory effects and the inhibition of neutrophil responsiveness by *Barleria lupulina* and *Clinacanthus nutans* extracts. *Journal of Ethnopharmacology*, 116(2), 234-244. DOI: 10.1016/j.jep.2007.11.035

[XXX]